

Quantifying the Sharpness of Osteotomes for Dorsal Hump Reduction

Jason D. Bloom, MD; Evan R. Ransom, MD; Marcelo B. Antunes, MD; Daniel G. Becker, MD

Objective: To assess the relative sharpness of osteotomes after multiple uses, routine maintenance, and sharpening.

Methods: This prospective clinical study and mechanical model quantified the relative sharpness of identical osteotomes at baseline; after 3, 6, and 9 uses; and after sharpening techniques compared with osteotomes from hospital central supply. The Instron universal tester developed a force-displacement curve as the osteotome blade cut a standardized suture. Force required to cut the suture is inversely proportional to osteotome sharpness.

Results: For osteotomes 1, 2, and 3, dullness occurred after 9 uses (4.836 lb; $P < .001$), 6 uses (4.431 lb; $P < .005$), and 3 uses (4.093 lb; $P < .02$), respectively. Osteotome 1 was professionally sharpened after 9 uses and retested

(3.156 lb); results were similar to those for an osteotome used 6 times (3.160 lb). Additional sharpening showed significantly poorer performance (7.737 lb; $P < .001$ at baseline and after 9 uses). Osteotome 3 was hand sharpened after 6 uses and retested (7.750 lb; baseline $P < .001$). Two osteotomes from central supply required almost twice the cutting force relative to the senior author's osteotomes.

Conclusions: Although osteotome performance decreased significantly over time, professional sharpening only achieved results similar to an osteotome used 3 to 6 times. Further reshaping seems detrimental to performance. Surgeons may want to consider osteotomes disposable instruments.

Arch Facial Plast Surg. 2011;13(2):103-108

RHINOPLASTY SURGEONS AGREE that a sharp osteotome is critical to achieving accurate results and reducing complications in dorsal hump reduction. Similar to the way in which a fresh scalpel improves dissection in soft-tissue surgery, a sharp osteotome allows more precise and controlled bone cuts. Microfractures and even large fractures of the bone can occur with increased frequency when using a dull osteotome, but a sharp osteotome surface tends to cut through the bone more smoothly and with more accuracy.¹ An ideal osteotomy provides exacting, predictable, and reproducible cosmetic and functional results while minimizing soft-tissue trauma and postoperative sequelae.^{2,3} Also, when removing the dorsal hump or performing bony osteotomies in rhinoplasty, the surgery is in close proximity to the cranial vault. Having sharp instruments allows for less force to be used during the light "tap tap" of the mallet, reducing the chance of a percussive effect on the brain.¹ There are many reasons to retain the sharpness of surgical instruments, but what tells the surgeon that it

is time for sharpening? Ultimately, the operating surgeon bears some responsibility for making these decisions and maintaining sharp and well-functioning surgical tools in the instrument set.¹

Although facial plastic surgeons have been performing nasal surgery and rhinoplasty for many decades, an evidence-based guideline has never been developed to compare the relative sharpness of rhinoplasty osteotomes. Also, no quantitative guidelines exist to direct the facial plastic surgeon to the most appropriate method of sharpening the osteotome and to the number of uses after which sharpening may be indicated. Because there are no specific indicators telling the surgeon to sharpen his or her instruments, current practice varies widely, ranging from surgeons who regularly sharpen their instruments after each procedure to those who wait a specified period (eg, "every 4 months") or after multiple procedures to sharpen their osteotomes. Without empirical support for a particular maintenance protocol, surgeons may rely solely on "feel" to determine the right time to sharpen their instruments or surgical tools.

Author Affiliations:
Department of Otorhinolaryngology–Head and Neck Surgery, University of Pennsylvania, Philadelphia (Drs Bloom, Ransom, Antunes, and Becker); and Becker Nose and Sinus Center, Sewell, New Jersey (Dr Becker).



Figure 1. A double-guarded Cinelli 10-mm osteotome used in this study for testing and also by the senior author (D.G.B.) for reduction of a dorsal nasal hump.



Figure 2. A, The Instron universal tester setup before an osteotome sharpness testing trial. B, Close-up view of the osteotome seated in its specially designed holder.

The experimental model described herein allows for accurate quantification of the sharpness of a rhinoplasty osteotome used for reducing the dorsal hump after multiple uses and different methods of sharpening. This research offers a general guideline and suggestions that provide the rhinoplasty surgeon with important quantitative information that may affect how surgical instruments and osteotomes are maintained.

METHODS

STUDY DESIGN

This study received an exemption approval from the institutional review board of the University of Pennsylvania, Philadelphia. We devised a prospective study to quantify the relative sharpness of rhinoplasty osteotomes for reducing the dorsal nasal hump and the difference in sharpness that occurs after multiple uses. In addition, we evaluated the difference in osteotome sharpness between having the instruments hand sharpened with a sharpening stone and those sent out for professional sharpening. All the rhinoplasty procedures were performed at a hospital-based, state of New Jersey–accredited, private practice surgical center, and the senior author (D.G.B.) performed all the dorsal hump removals. The osteotomes were tested for sharpness at the University of Pennsylvania Mechanical Testing Central Facility.



Figure 3. Close-up view of the testing setup and the holders that were created for the osteotomes and the No. 2 monofilament polypropylene suture.

OSTEOTOME TESTING

After 3, 6, and 9 uses for reduction of the osseocartilaginous dorsal nasal hump, each osteotome was tested to quantify its sharpness. The experiments were performed using 10-mm double-guarded stainless steel Cinelli osteotomes (model N-4380; Storz, Tuttlingen, Germany), which the senior author (D.G.B.) routinely uses for dorsal hump reduction in rhinoplasty (**Figure 1**). Three osteotomes from the same manufacturer and with the same bevel degree, size, shape, weight, metal, and original factory sharpness were used. To test and quantify the sharpness of each osteotome, we used an Instron universal tester (model 4206; Instron, Norwood, Massachusetts) with an extremely sensitive 100-N load cell (Catalog No. 2525-807; Instron). A specific holder for the osteotome was constructed by a biomedical machinist (**Figure 2**). In addition, a holder for a No. 2 (5.0 metric) monofilament polypropylene suture (Prolene; Ethicon Inc, Somerville, New Jersey) was constructed. The suture is fixed at one end and attached to a standardized 370-g dead weight at the other end to apply constant tension (**Figure 3**). Using the Instron universal tester and its holder, each osteotome was then advanced against the suture until the suture was severed by the blade. The Instron universal tester developed a force vs displacement curve, and the force at the point where the suture is cut is inversely proportional to the sharpness of the blade. After quantifying the sharpness, the edges of the osteotomes were then visualized using a high-powered optical microscope (Olympus BH-2; Olympus Inc, Melville, New York) to compare the appearance of the cutting surface.

In a second experiment, we looked at the sharpness of other osteotomes from rhinoplasty sets throughout the University of Pennsylvania Health System to evaluate their relative sharpness. This gave us a sense as to whether the osteotomes from these sets or those maintained separately for a rhinoplasty private practice at a surgical center retained instrument sharpness more effectively.

SHARPENING SETUP

One osteotome was sharpened by hand using a moistened Arkansas fine-grit sharpening whetstone. We used a previously published hand-sharpening protocol determined by Gryskiewicz and Gryskiewicz.³ The osteotome in this arm of the experiment was hand sharpened by a single operator (J.D.B.) using a specific method. The number of sharpening strokes on each side of the osteotome was standardized to 21, according to the previously mentioned protocol. There were 10 forward strokes on each side with pressure, and care was taken to push the osteotome at a 30° inclination, retaining the standard point on the osteotome. Next, there were 10 additional forward strokes on each side with less pressure and a steeper angle of 45°, followed by a single light stroke on each side at a 60° inclination to complete the sequence. The osteotome sharpness was then again tested using the Instron universal tester.

Finally, one osteotome was sent to a surgical instrument company for professional sharpening using a motorized water wheel. Once returned, the osteotome was again tested for sharpness using the Instron universal tester.

STATISTICAL ANALYSIS

For each osteotome, sharpness was quantified as the pounds of force necessary to cut a No. 2 monofilament polypropylene suture. Four trials for each osteotome were recorded and averaged at each time point (at baseline and after 3, 6, and 9 uses). Comparison of osteotome sharpness between time points was performed using paired-sample *t* tests. The different osteotomes were compared using unpaired *t* tests. All the analyses were performed using 2 tails. Statistical significance was set at $P < .05$. Statistical analyses were performed using a software program (SigmaStat, version 3.1; Systat Software Inc, San Jose, California).

RESULTS

OSTEOTOME EFFICACY DECREASES WITH CONTINUED USE

In the first experiment, we tested the efficacy of 3 new and identical osteotomes. These osteotomes, which were all produced by the same manufacturer, have the specifications of instruments that were routinely used by the senior author (D.G.B.) and that are maintained at his private office and surgery center. For osteotome 1, baseline values were taken before any use in the operating room (ie, when the blade was new from the factory), and an average of 4 individual tests displayed that 3.083 lb was required to cut the suture. After 3 and 6 uses, this value increased (to 3.084 and 3.160, respectively), but there was no significant difference between values at baseline and at either subsequent time point ($P > .99$ and $P = .57$, respectively). After 9 uses, however, an average of 4.836 lb was required to cut the suture, which was significantly different than the baseline value ($P < .001$) and the value after 6 uses ($P < .001$). This corresponded to a subjective observation by the author that the osteotome had dulled.

With osteotomes 2 and 3, a similar increase in the force required to break the suture was observed after increased use. These osteotomes also were brand new before each baseline testing for this study. For osteotome 2, the baseline value was 2.442 lb. This value increased

to 2.683 lb after 3 uses ($P = .06$) and to 4.431 lb after 6 uses, resulting in a significant difference from the baseline value ($P < .005$) and the value after 3 uses ($P < .008$). For osteotome 3, the baseline value was 3.173 lb. The pounds of force necessary for the osteotome to cut the suture increased significantly after 3 uses to 4.093 lb ($P < .02$). Additional use resulted in a further decrease in sharpness, as reflected in the significant increase in force required to break the suture (an average of 4.734 lb) ($P < .02$ for 6 previous uses relative to 3 previous uses). For all 3 osteotomes, the significant change in osteotome sharpness also corresponded to a subjective feeling of instrument dullness noted by the senior author (D.G.B.). Examination under a high-powered optical microscope of the cutting edges of a brand-new osteotome and one that had been used 9 times showed striking differences. An extremely rough edge was visualized on the used osteotome, with irregularities and wire shards coming off the cutting surface, vs a clean and sharp edge seen on the new osteotome (**Figure 4**).

EFFECTS OF PROFESSIONAL SHARPENING AND HAND SHARPENING

To assess the effects of sharpening on osteotome efficacy, 2 osteotomes were sharpened and then retested. First, osteotome 1 was professionally sharpened by an independent contractor after its ninth use. This resulted in a mean of 3.156 lb after retesting, which was not significantly different than the baseline value of 3.083 lb ($P = .69$) but was only as sharp as if the osteotome had been used 6 times (3.160 lb). After testing the sharpened osteotome, we returned it to the professional sharpener with the specific request that the blade be re-sharpened to a shape as close to “new” as possible. Osteotome 1 was subsequently tested again, resulting in a significantly poorer performance. On average, 7.737 lb was required to cut the suture, which was significantly greater than the baseline value and the value obtained after 9 uses ($P < .001$ for both). Gross visual and microscopic examination of the blade at this point revealed substantial loss of metal and mass at the osteotome tip and deformity of the cutting surface (**Figure 5**).

In addition to professional sharpening, we assayed the effect of hand sharpening an osteotome by ourselves (as described in the “Methods” section). Osteotome 3 was sharpened by us after 6 uses and then was retested. This resulted in an average of 7.750 lb being required to cut the suture, which was significantly greater than the baseline value ($P < .001$). High-powered microscopic examination of the hand-sharpened osteotome surface demonstrated many irregularities to the osteotome cutting surface that were not seen on examination of a new osteotome (Figure 4).

HOSPITAL-MAINTAINED OSTEOTOMES

In a final experiment, we tested the efficacy of 2 osteotomes maintained by the University of Pennsylvania Health System hospital operating room central supply in the standard instrument sets: 1 from an affiliated hospital and 1 from the outpatient surgery center used by the




Figure 4. High-resolution optical microscopy of the osteotome cutting surfaces. A, Close-up view of an osteotome cutting edge that is new from the manufacturer (original magnification $\times 10$). B, Close-up view of the rough edge of an osteotome seen after 9 uses (original magnification $\times 10$).




Figure 5. Difference visualized between a brand-new osteotome (A) and an osteotome with too much metal removed behind the cutting surface after excessive professional sharpening (B).

Department of Otorhinolaryngology–Head and Neck Surgery. In the first assay, a Cinelli osteotome was borrowed from a freshly processed instrument tray at an affiliated hospital, and an average of 10.616 lb was required to break the No. 2 monofilament polypropylene suture. In the second assay, a Ruben osteotome was borrowed from the outpatient surgery center, and an average of 8.955 lb was required to cut the suture. Each of these values was significantly greater and almost 2 times the pounds of force needed to cut the suture compared with being used 9 times with osteotome 1, 6 times with osteotome 2, and 3 times with osteotome 3. These comparisons were made after each of these 3 osteotomes was already considered significantly “dull.”

COMMENT

Predictable and precise control of osteotomy placement is important.⁴ The sharper the osteotome, the less force is required to make cuts, and the more accurate and controllable the osteotomy. Sharp osteotomes increase accuracy and surgical predictability by minimizing the forces necessary to achieve precise osteotomies.⁴ Tebbetts⁴ explains that for optimal performance in rhinoplasty surgery, the surgeon should sharpen osteotomes after each use. He further elucidates that a “fresh, razor sharp osteotome is impressive compared to a similar osteotome that has been used previously.”^{4(p243)} This “impressive” sharpness is determined only by the feel of an experienced surgeon and has never been quantified.

The judgment of the operating surgeon is an important factor in determining when an osteotome should be sharpened or replaced. With this in mind, there are certain risks that relate to dorsal hump removal that may be reduced with a sharper osteotome. An osteotome that is becoming dull requires more force to remove a dorsal hump. Because the bone of the dorsal hump is thicker at its more superficial aspect and thinner at its deeper aspect, a dull osteotome may take a “path of least resistance” and result in a deeper bone cut and greater bony hump resection. This may lead to overresection of the bony hump. Also, a dull osteotome may be more difficult for the surgeon to control as precisely as a sharp osteotome and may be more likely to produce microfractures in the bone during dorsal hump removal that can translate into dorsal irregularities.

Whereas Tebbetts⁴ suggested that an osteotome should be sharpened after each use, the present initial study in-

licated that it took multiple uses to significantly dull the osteotome that was tested. This study was designed to determine the optimal number of uses after which surgical osteotomes should be sharpened or replaced so that all patients undergoing dorsal hump reduction might benefit from “impressive” sharpness. Of course, these results are preliminary.

There has been some periodontal and dental literature using scanning electron microscopy to evaluate instrument sharpness and then comparing the effectiveness of different types of sharpening techniques. However, these studies do not specify how many times each instrument had been used before sharpening, and they do not use quantitative data to measure relative sharpness. In a study by Moses et al,⁵ the presence of a “wire edge” on the instrument cutting surface and the bevel were evaluated, but sharpness was not specifically measured or quantified. A study by Rossi and Smukler⁶ evaluated the root surfaces of teeth using scanning electron microscopy and graded the smoothness of the tooth roots as a marker for sharpness of the periodontal curette. Again, only scanning electron microscopy was used to determine sharpness, and the relative data were never quantified into numbers, quantifying the actual sharpness of the instrument.

The bony dorsal hump may be reduced using a rasp or an osteotome. When using an osteotome, it is crucial to use a sharp instrument. To accurately reduce the bony nasal dorsum, a sharp osteotome is advanced cephalically to remove the desired degree of bone.⁷ We believe that a sharp osteotome is an essential tool in the precise takedown of the bony dorsal nasal hump.⁸ Also, we agree with Tebbetts,⁴ who writes that composite reduction of the osseocartilaginous nasal dorsum should be undertaken using a “razor sharp osteotome” to control millimeters of the dorsum with precise reliability. As an osteotome dulls, the risk of asymmetrical resection or overresection of the nasal dorsum may increase.⁸

The best method of osteotome sharpening has been debated. Although some facial plastic surgeons send their osteotomes to a professional sharpening service, others insist on sharpening the instruments themselves using ceramic sharpening stones, diamond stones, or fine-grit whetstones. Some argue that the commercial sharpening services remove too much metal during the sharpening process, shortening the osteotome life. These surgeons assert that manual sharpening allows for better control of the osteotome tip with less removal of metal. It has also been noted that loupe magnification is helpful in achieving the most even taper of the osteotome tip.⁴ Some surgeons recommend keeping multiple sharp osteotomes available at all times in the rhinoplasty instrument set and storing them separately so as not to have them come into contact with other instruments.⁴ This idea has been echoed by others who purchase multiple sets of osteotomes and rotate them out of use so that one set is always off being professionally sharpened. Although there is no definitively correct frequency or technique for sharpening an osteotome, we hope that this study and further studies help clarify this subject.

Furthermore, the Cinelli osteotomes used in this study were made of stainless steel and were purchased from a single manufacturer. Although these osteotomes were chosen because they were the current instruments of choice for the senior author (D.G.B.), many instrument companies have experimented with different metals and alloys to produce an osteotome that is sharper, stronger, and holds a sharpened edge better. We are currently performing additional testing by looking at different alloys, metal coatings, and instrument manufacturers to assess baseline sharpness and the maintenance of a sharpened edge between osteotomes.

It is evident that osteotomes dull with repeated use. This study examined and quantified this dulling effect. Of course, this is a limited, preliminary study in which only 3 osteotomes from a single manufacturer were tested. Further ongoing research may determine the extent to which these results more generally apply.

The surgeon has several options in addressing a dull surgical instrument. The surgeon may resharpen osteotomes with a sharpening stone or have the instruments professionally sharpened. In this study, these actions led to persistently dull instruments. An additional option is to return the instrument to the manufacturer for sharpening. This sharpening method is currently under investigation.

Another alternative is to consider these instruments to be disposable. Further study is necessary to determine how many uses are acceptable before disposal. The osteotomes used in this study for dorsal hump reduction currently cost approximately \$150. The senior author (D.G.B.) no longer sharpens his osteotomes but rather limits their use. Similar to a scalpel blade, he now considers the osteotome to be a disposable instrument.

In conclusion, sharp osteotomes are critical to producing precise results in the reduction of the bony dorsal hump in rhinoplasty. In this study, the osteotomes became significantly “dull” after 3 to 9 dorsal hump reductions. However, professional sharpening could achieve only the sharpness equal to an osteotome used approximately 6 times. Further sharpening may remove too much metal and can be detrimental to osteotome performance. Surgeons may want to consider osteotomes to be disposable instruments. This study provides the rhinoplasty surgeon with important quantitative information that may affect how surgical instruments are maintained.

Accepted for Publication: November 1, 2010.

Corresponding Author: Daniel G. Becker, MD, Becker Nose and Sinus Center, 400 Medical Center Dr, Ste B, Sewell, NJ 08080 (beckermailbox@aol.com).

Author Contributions: Dr Becker had full access to all the data in the study and takes responsibility for the integrity of the data and the accuracy of the data analysis. *Study concept and design:* Bloom, Ransom, and Becker. *Acquisition of data:* Bloom, Ransom, and Antunes. *Analysis and interpretation of data:* Bloom, Antunes, and Becker. *Drafting of the manuscript:* Bloom and Ransom. *Critical revision of the manuscript for important intellectual content:* Bloom, Antunes, and Becker. *Statistical analysis:* Bloom and Ransom. *Obtained funding:* Bloom and Becker.

Administrative, technical, and material support: Bloom, Antunes, and Becker. *Study supervision:* Becker.

Financial Disclosure: None reported.

Previous Presentation: This study was presented as a poster presentation at the American Academy of Facial Plastic and Reconstructive Surgery fall meeting; September 23-26, 2010; Boston, Massachusetts.

Additional Contributions: Alex Radin, PhD, and the University of Pennsylvania Mechanical Testing Central Facility helped with study setup and osteotome testing and assisted in the manufacturing of the osteotome, the suture holders, and the actual testing device. Also, Lolita Rotkina, PhD, at the University of Pennsylvania Regional Nanotechnology Facility helped with the high-powered optical microscopic photographs of the osteotome edge.

REFERENCES

1. Wolfe SA. On the maintenance and sharpening of instruments. *Plast Reconstr Surg.* 2005;116(5)(suppl):89S-91S.
2. Lee HM, Kang HJ, Choi JH, Chae SW, Lee SH, Hwang SJ. Rationale for osteotome selection in rhinoplasty. *J Laryngol Otol.* 2002;116(12):1005-1008.
3. Gyskiewicz JM, Gyskiewicz KM. Nasal osteotomies: a clinical comparison of the perforating methods versus the continuous technique. *Plast Reconstr Surg.* 2004;113(5):1445-1458.
4. Tebbetts JB. *Primary Rhinoplasty: Redefining the Logic and Techniques.* 2nd ed. Philadelphia, PA: Elsevier; 2008.
5. Moses O, Tal H, Artzi Z, Sperling A, Zohar R, Nemcovsky CE. Scanning electron microscope evaluation of two methods of resharpener periodontal curets: a comparative study. *J Periodontol.* 2003;74(7):1032-1037.
6. Rossi R, Smukler H. A scanning electron microscope study comparing the effectiveness of different types of sharpening stones and curets. *J Periodontol.* 1995;66(11):956-961.
7. Behrbohm H, Thomas JR, Tardy ME. *Essentials of Septorhinoplasty: Philosophy, Approaches, Techniques.* New York, NY: Thieme; 2004.
8. Becker DG, Park SS. *Revision Rhinoplasty.* New York, NY: Thieme; 2008.

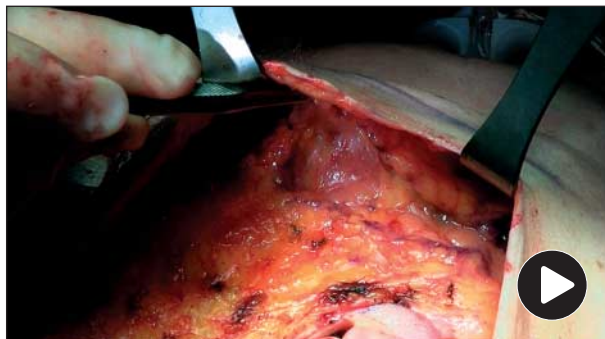
Techniques in Facial Plastic Surgery

SMAS Flap Rhytidectomy

Jon-Paul Pepper, MD; Shan R. Baker, MD

We describe a variation of sub-superficial musculoaponeurotic system (SMAS) rhytidectomy. An incision in the SMAS is made from the lateral malar eminence to the angle of the mandible. A SMAS flap is raised and then imbricated directly onto the periparotid fascia after posterosuperior advancement.

Visit <http://www.archfacial.com> to view a video demonstrating this technique.



Sub-superficial musculoaponeurotic system flap rhytidectomy.

Author Affiliations: Department of Otolaryngology-Head and Neck Surgery, University of Michigan, Alfred Taubman Health Care Center, Ann Arbor.