



## Auricular cartilage grafts

Jacob D. Steiger, MD,<sup>a</sup> Jason Bloom, MD,<sup>b</sup> Daniel G. Becker, MD<sup>b,c</sup>

From the <sup>a</sup>Center for Facial Cosmetic Surgery, University of Michigan, Livonia, Michigan;

<sup>b</sup>Department of Otolaryngology, University of Pennsylvania Medical Center, Philadelphia, Pennsylvania; and the

<sup>c</sup>Department of Otolaryngology, University of Virginia Medical Center, Charlottesville, Virginia.

### KEYWORDS

Rhinoplasty;  
 Revision rhinoplasty;  
 Auricular cartilage;  
 Autogenous grafts;  
 Auricular cartilage  
 graft;  
 Nasal surgery

The rhinoplasty surgeon often encounters the need to utilize nasal grafts when performing primary or revision surgery. While there are a myriad of grafting materials to choose from, long-term success has been achieved with autogenous cartilage. In revision surgery, septal cartilage is often unavailable and the surgeon must look to alternate donor sites. Auricular cartilage is a versatile graft material that can be successfully used to treat a wide range of nasal defects without major complications.

© 2008 Elsevier Inc. All rights reserved.

The rhinoplasty surgeon often encounters the need to use grafts when performing primary or revision surgery. Septal cartilage is typically the graft material of choice. However, patients who have had previous nasal surgery may lack adequate septal cartilage for structural grafting. In these circumstances, the surgeon must look to alternative sources. A variety of alternative grafting materials are available to the surgeon. They may be classified as autografts (native cartilage, bone, fascia, dermis), homografts (irradiated rib, pooled acellular dermis), and alloplasts (Silastic, Mersilene, Gore-Tex, Medpor).

The properties of an ideal structural nasal graft material include that it should be biocompatible, resistant to infection, nonresorbable, easily manipulated, structurally sound, noncarcinogenic, easy to obtain, cost-effective, and having a feel similar to the native nasal framework. With this in mind, the choice of grafting material should maximize the chance of long-term success and minimize the risk of morbidity.

Homografts are a potentially attractive material for structural nasal grafting. Nasal surgeons have used these grafts in large quantities throughout the past century. Irradiated rib is human-derived, sturdy, and does not require a separate surgical donor site. However, reports of unpredictable behavior and of an increased rate of resorption, and the potential for warping, have precluded its widespread ac-

ceptance.<sup>1,2</sup> Acellular dermis (AlloDerm; LifeCell, Inc, Branchburg, NJ) is another homograft that may be used for nasal grafting. Its plasticity limits its use to soft-tissue augmentation.

A variety of alloplastic implants have been used as nasal grafts during the past century. They have the obvious advantages of an abundant supply, no donor sites, and their availability in different shapes and sizes. Although they have been successfully used as grafting materials in other regions of the body, the authors believe that alloplasts have not proven to be as successful in the nose over time. The thin nasal skin and soft tissue, as well as its predilection for continuous motion and trauma, make the nose an unforgiving host site. These factors may contribute to infection and extrusion when alloplasts are used as nasal grafts.

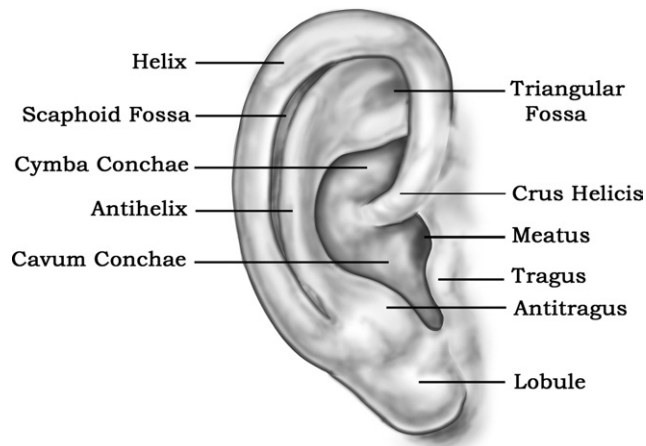
Nasal surgeons continue to report on the success of newer alloplastic implants.<sup>3,4</sup> On the basis of past experience, with the momentary success of prior synthetic implants, we believe that these reports should be considered with guarded optimism.

Nasal surgeons have used cartilaginous autografts from the nose, auricle, and rib with great success over time. Cartilaginous autografts have the benefit of superior long-term survival, availability in the head and neck, and resistance to resorption and infection.<sup>5</sup> The natural plasticity of autogenous cartilage affords it success as a structural graft. Additionally, plasticity may be augmented by cross-hatching or morsalization to serve a broader range of functions. Cartilage grafts are highly durable. They may be successfully placed into precise pockets or stacked in layers to

---

**Address reprint requests and correspondence:** Jacob D. Steiger, MD, University of Michigan, Center for Facial Cosmetic Surgery, 19900 Haggerty Road, Ste 101, Livonia, MI 48105.

E-mail address: [jdsteiger@gmail.com](mailto:jdsteiger@gmail.com).



**Figure 1** Important topographic features of the ear.

augment nasal depressions. Predictable and long-lasting results have made them the choice grafts for generations of experienced surgeons.<sup>6</sup>

The senior author uses the time-tested approach of autogenous cartilage grafting in nasal reconstruction. The autograft material of choice is most commonly the nasal septum. When performing revision rhinoplasty, we first look to the septum for residual cartilage. An ample supply of cartilage can often be found despite a history of prior septoplasty. In cases where the septal cartilage is missing or insufficient, we turn to the auricle.

Auricular cartilage is a great source for structural nasal grafts. Its ease of harvest from the same surgical field and minimal donor site morbidity make it an excellent choice. Segments of 3.5 to 4.0 cm are commonly available. In most patients, the cartilage is stiff yet pliable, and warping rarely occurs.<sup>5</sup> The natural curve of the auricular cartilage may mimic native structures and be of benefit in graft design. Graft presence is rarely bothersome to the patient, as its properties are similar to that of the native nasal tissues.

Auricular cartilage grafts have also been successfully used in the pediatric population.<sup>7</sup> Leaving one perichondrial surface intact has demonstrated to allow for graft growth in conjunction with the host.<sup>8</sup> We additionally use the auricular donor site for composite grafts of skin and cartilage. In this article, we will review the use of auricular cartilage in revision rhinoplasty. The harvesting surgeon must first have a thorough understanding of the external ear anatomy. Careful planning from graft harvest to design must then be undertaken to gain maximal benefit from the auricular cartilage.

### Auricular cartilage: Anatomy

The harvesting surgeon must have a thorough understanding of the external ear anatomy (Figure 1). Among the important topographic features of the ear is the prominent rim of the auricle known as the helix. Parallel and anterior to the helix is another prominence known as the antihelix or antihelical fold. As it traverses superiorly, the antihelix divides into a superior and an inferior crus that border the fossa triangularis. The depression between

the helix and antihelix is known as the scapha or scaphoid fossa. The antihelical fold surrounds the concha, a deep cavity posterior to the external auditory meatus. The crus helicis, representing the helical root, divides the concha into a superior portion, the cymba conchae, and an inferior portion, the cavum conchae. The cavity formed by the concha on the anterior (lateral) surface of the ear corresponds to a bulge or convexity on the posterior (medial) surface of the ear that is known as the eminentia of the concha.

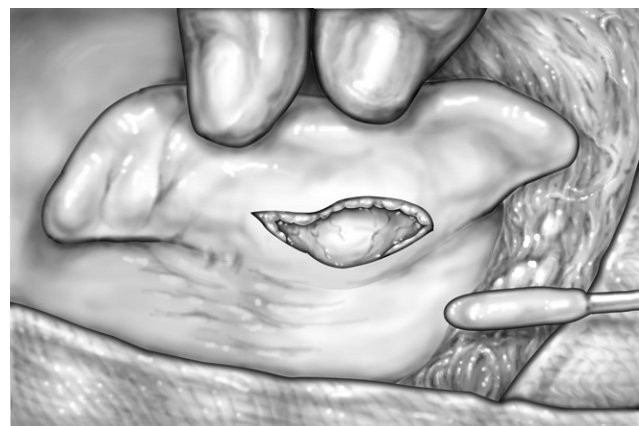
Anterior to the concha and partially covering the external auditory meatus is the tragus. The antitragus is posteroinferior to the tragus and is separated from it by the intertragic notch. Below the antitragus is the lobule that is composed of areolar tissue and fat.<sup>9</sup>

Except for the lobule, the auricle is supported by thin, flexible fibroelastic cartilage. This cartilaginous framework is 0.5 to 1.0 mm thick and covered by minimal subcutaneous tissue.<sup>10</sup> The skin is loosely adherent to the posterior surface and helix of the auricular cartilage. The close approximation of the skin to the anterior surface of the cartilage provides the auricle with its unique topographic features.

### Auricular cartilage: Harvest

Because the external ear is an excellent reservoir of structural grafts for rhinoplasty, the majority of our extranasal grafts are taken from it. Grafts are harvested anterior to the border of the common and inferior crus of the antihelical fold (the cymba concha and/or the cavum concha). Because the antihelix serves as the structural buttress of the external ear, grafts harvested from the concha do not alter the ear's external appearance. Care must be taken as to not transgress the antihelix for this reason.

Graft-side harvest is typically determined by several factors. If the patient favors sleeping on one side of the head, the graft should be harvested from the contralateral side. In addition, removal of the entire concha may reduce the auriculomastoid angle, bringing the auricle closer to the head.



**Figure 2** The patient's hair is controlled by lubricating it with Bacitracin ointment. When the posterior approach is used, an incision is made in the postauricular skin that overlies the eminentia of the concha.

In patients with asymmetric angles, the cartilage should be harvested from the more protruding ear.<sup>5</sup> Preservation of the lateral walls of the concha and the radix helices prevents the medial displacement of the auricle when this is not desired.<sup>11</sup> Because graft design is not affected by the side of harvest, it is not a determining factor when choosing the donor side.

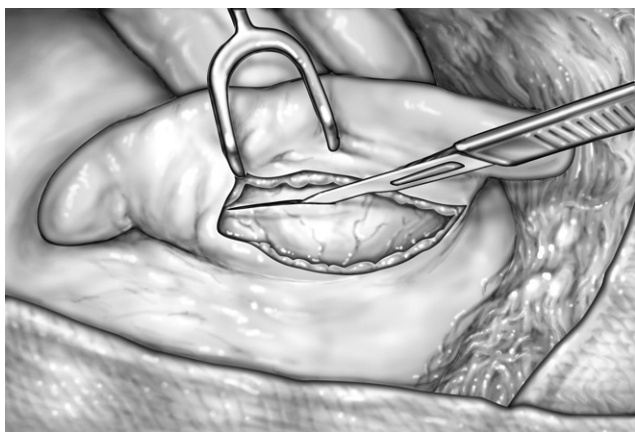
The auricular cartilage harvest is approached from either the anterior or posterior surface of the auricle. For the less-experienced surgeon, the anterior approach may allow for a greater amount of cartilage to be removed. The posterior approach offers the advantage of a well-hidden incision. We find that either approach affords appropriate exposure to achieve the desired cartilage harvest.

Systemic preoperative antibiotics are administered, and the ear is prepped and draped in continuity with the surgical field. The patient's hair is controlled by lubricating it with Bacitracin ointment (Figure 2). 1% xylocaine solution with 1:100,000 epinephrine is injected into the subperichondrial plane of the anterior conchal surface. This mixture allows for hydrodissection of the perichondrium and skin from the underlying cartilage and facilitates a bloodless dissection. The posterior surface soft tissue is also injected.

When the anterior approach is used, an incision is designed inferomedial to the overhang of the antihelix and follows the lateral border of the cavum and cymba concha. This ensures the appropriate camouflage of the resultant scar. The incision is made with a #15 blade and a wide flap is elevated in the subperichondrial plane. The dissection proceeds using scissors and blunt dissectors (Freer elevator and cotton-tip applicators), with the surgeon taking care not to damage the soft auricular cartilage. The dissection stops short of the cartilage of the external auditory canal. When removing the cymba and cavum concha, the radix helices is preserved to maintain the auriculomastoid angle.

The desired piece of cartilage is then sharply incised and the posterior surface is exposed. Using the appropriate scissors, the surgeon dissects the posterior surface, leaving perichondrium attached to cartilage. Deep dissection is avoided to minimize soft tissue bleeding.

When the posterior approach is taken, an incision is made in the postauricular skin that overlies the ementia of

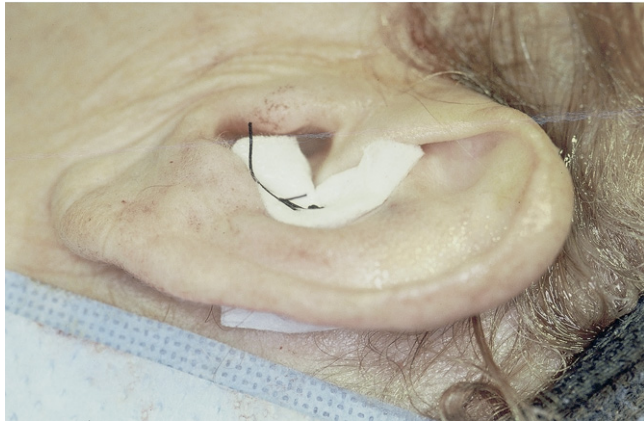


**Figure 3** The skin and soft tissue is elevated over the ementia, and the desired cartilage is sharply incised. Care is taken to preserve the cartilage of the antihelical fold as well as the crus helices.

**Figure 4** In A-C, the anterior flap is elevated in the subperichondrial plane.

the concha (Figure 2). The skin and soft tissue are elevated over the ementia, and the desired cartilage is sharply incised (Figure 3). Care is taken to preserve the cartilage of the antihelical fold as well as the crus helices. The anterior flap is elevated in the subperichondrial plane (Figures 4 and 5), and the cartilage is removed.

Meticulous attention is then given to hemostasis of the surgical field and the wound is irrigated with sterile saline. The incision is closed with a 6-0 fast-absorbing suture, everting the skin edges. A bolster dressing of Telfa, dental roll, or other suitable material is fashioned, placed in the conchal bowl, and sutured into place to prevent the formation of a hematoma (Figure 5).



**Figure 5** A bolster dressing of Telfa, dental roll, or other suitable material is fashioned, placed in the conchal bowl, and sutured into place to prevent the formation of a hematoma-photo. (Color version of figure is available online.)

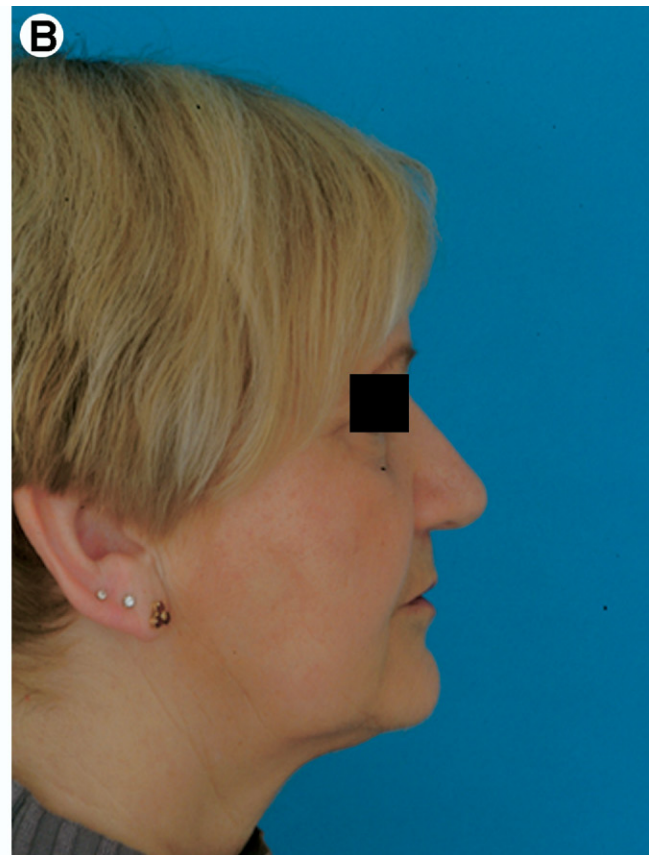
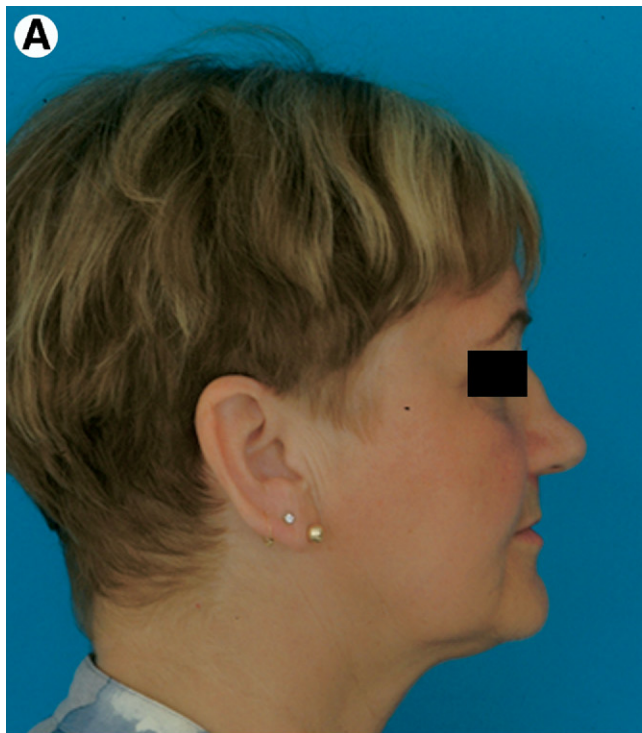### Auricular cartilage applications

Once the auricular cartilage is harvested, the graft design must be carefully planned to meet the specific needs of the individual patient. Cartilage harvested from the cymba concha tends to be flatter, whereas cartilage from the cavum conchae has a more curved topography. The curved nature of the graft specimen can be favorably exploited when carving individual nasal grafts. When necessary, curved portions may be flattened through unilateral cross-hatching

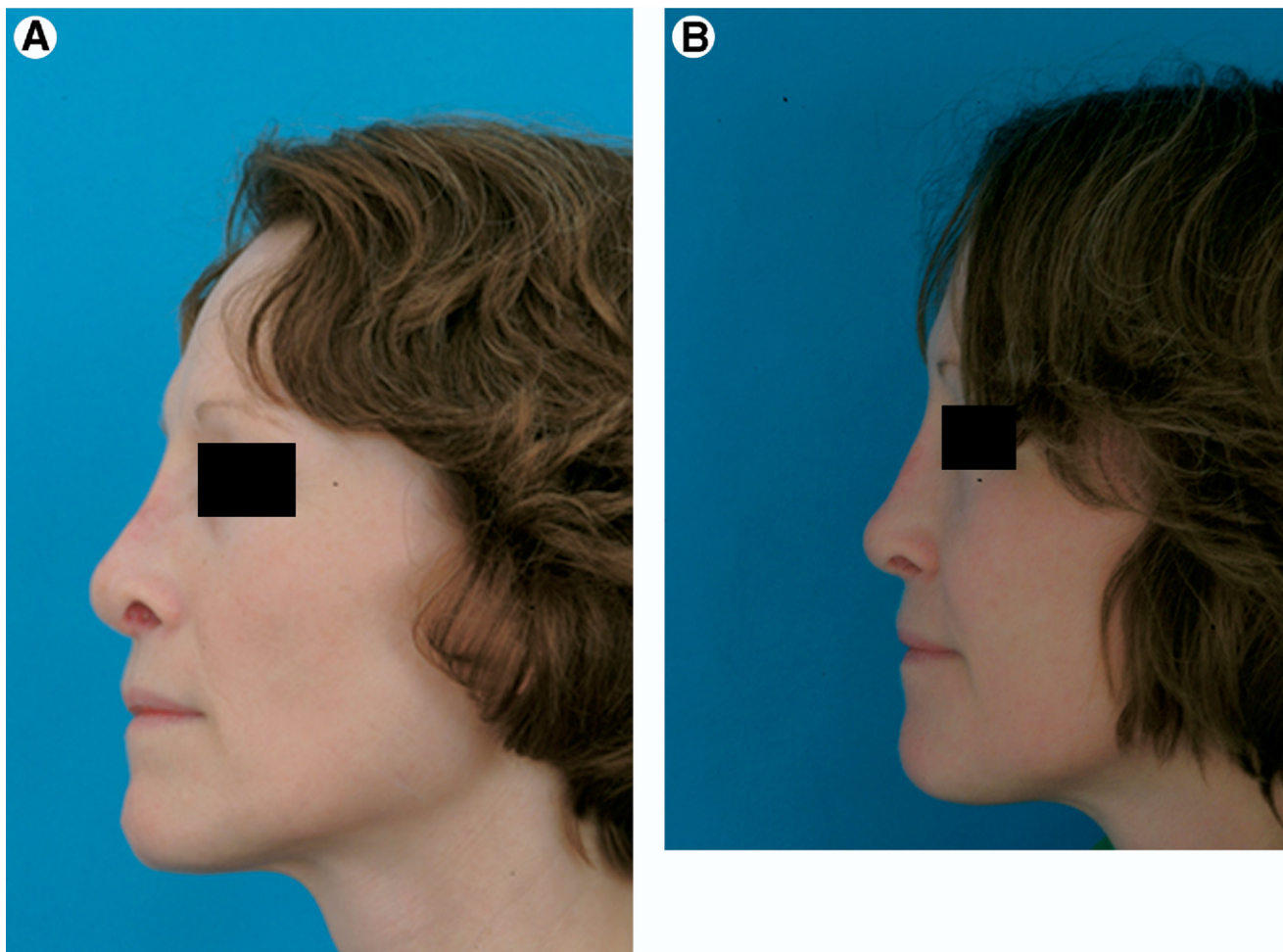techniques. The cartilage can also be morselized and used as filler. Understanding the nasal deficit and graft demands before carving allows the surgeon to obtain consistent success using auricular cartilage.

Commonly used nasal grafts can be prepared from the harvested auricular cartilage. These include but are not limited to nasal tip grafts, shield grafts, columellar strut grafts, dorsal onlay grafts, spreader grafts, alar batten grafts, lateral crural strut grafts, septal replacement grafts, plumping grafts, and radix grafts. A unilateral auricular cartilage harvest is often sufficient for reconstruction. In cases where more significant quantities of graft material are required, bilateral auricular cartilage grafts may be harvested. The list of potential applications of auricular cartilage in revision rhinoplasty is exhaustive. Selected applications are discussed here.

The saddle nose is a commonly encountered problem arising from trauma, infection, or from prior nasal surgery. In moderate deformities, single or multilayer, laminated cartilage grafts can be successfully used for repair (Figure 6). We commonly obtain these grafts from the superior cymba concha along the antihelical rim. Grafts from this region are flatter and shaped similarly to that of the natural nasal dorsum.<sup>12</sup> In patients with thin skin, care must be taken to smooth out and bevel the edges of the graft so that it is not palpable or visible. To camouflage contour irregularities in thin-skinned patients, we will wrap the graft in fascia or Alloderm as deemed appropriate. Abundant remaining soft tissue on the posterior surface of the graft may also serve as camouflage in this setting.



**Figure 6** (A and B) In moderate deformities, single or multilayer, laminated cartilage grafts can be successfully used for repair. This patient underwent augmentation with a triple layer auricular cartilage onlay graft, via an endonasal approach. (Color version of figure is available online.)



**Figure 7** (A and B) Patients such as this one, with severe alar retraction, require composite grafts of skin and cartilage. (Color version of figure is available online.)

In cases of severe nasal dorsal collapse, structural auricular cartilage grafts may not be sufficient. When encountered, cranial bone or autogenous rib grafts may be used to form intercalated L-struts for reconstruction.<sup>13-15</sup> Irradiated rib grafts have also been described for this use.<sup>16</sup>

Alar batten grafts are commonly necessary in revision rhinoplasty where nasal valve collapse has been found to exist.<sup>17</sup> This commonly stems from inadequate strength of the remaining lateral alar crus after cephalic resection. The innate curvature of auricular cartilage makes it an inherently useful graft for this purpose. A supraperichondrial pocket is made along the nostril rim and extends down to the pyriform aperture. The inserted graft functions to stiffen the lateral alar sidewall and improve nasal valve collapse.

Alar retraction is another common problem encountered in revision rhinoplasty. Patients with severe alar retraction may require composite grafts of skin and cartilage (Figure 7).<sup>18</sup> The auricular donor site is ideal for these types of defects. The availability of a naturally curved piece of cartilage and the ability to incorporate skin with the graft make it an excellent choice. Composite grafts may be taken individually or as part of a more extensive cartilage harvest.

Auricular cartilage can also be successfully used to replace other failed nasal grafts. Alloplastic implants are often removed when they become infected, extrude, or cause excessive pain. Autogenous auricular cartilage grafting is

safe, and we have had lasting success with it when used in this setting.

## Conclusion

Nasal grafting is often necessary to achieve successful surgical outcomes in rhinoplasty. The ideal grafting material does not yet exist. We believe that the surgeon should choose an implant material that he or she believes provides the potential for greatest success and minimal morbidity. The characteristics of cartilaginous autografts fulfill many of the criteria for the ideal implant. Long-term success has been achieved with their use, and they remain our grafts of choice. Septal cartilage is often preferred because of its availability at the surgical site and its inherent structural properties. When insufficient or unavailable, the external ear is our favored donor site. Auricular cartilage is a versatile graft material. It can be used successfully in correcting a wide range of nasal defects with no major complications.

## References

1. Adams WP Jr, Rohrich RJ, Gunter JP, et al: The rate of warping in irradiated and nonirradiated homograft rib cartilage: A controlled comparison and clinical implications. *Plast Reconstr Surg* 103:265-270, 1999

2. Welling DB, Maves MD, Schuller DE, et al: Irradiated homologous cartilage grafts. Long-term results. *Arch Otolaryngol Head Neck Surg* 114:291-295, 1988
3. Romo T 3rd, Kwak ES, Sclafani AP: Revision rhinoplasty using porous high-density polyethylene implants to reestablish ethnic identity. *Aesthetic Plast Surg* 30:679-684, 2006; discussion 685
4. Godin MS, Waldman SR, Johnson CM Jr: Nasal augmentation using Gore-Tex. A 10-year experience. *Arch Facial Plast Surg* 1:118-121, 1999; discussion 122
5. Tardy ME: *Rhinoplasty: the Art and the Science*. Philadelphia, Saunders, 1997, pp v.1-2
6. Tardy ME Jr, Denny J 3rd, Fritsch MH: The versatile cartilage autograft in reconstruction of the nose and face. *Laryngoscope* 95:523-533, 1985
7. Murrell GL: Auricular cartilage grafts and nasal surgery. *Laryngoscope* 114:2092-2102, 2004
8. Brent B. The acquired auricular deformity. A systematic approach to its analysis and reconstruction. *Plast Reconstr Surg* 59:475-485, 1977
9. Ballenger JJ, Snow JB: *Otorhinolaryngology: Head and Neck Surgery*. Baltimore, Williams & Wilkins, 1996, pp xiii
10. Weerda H: Embryology and structural anatomy of the external ear. *J Anat* 525, 1934
11. Johnson CT: *A Case Approach to Open Structure Rhinoplasty*. Amsterdam, Elsevier, 2005
12. Rodriguez-Camps S: Augmentative rhinoplasty with an "auricular gibbus." *Aesthetic Plast Surg* 22:196-205, 1998
13. Daniel RK: Rhinoplasty and rib grafts: Evolving a flexible operative technique. *Plast Reconstr Surg* 94:597-609, 1994; discussion 591-610
14. Gunter JP, Clark CP, Friedman RM: Internal stabilization of autogenous rib cartilage grafts in rhinoplasty: a barrier to cartilage warping. *Plast Reconstr Surg* 100:161-169, 1997
15. Tardy ME Jr, Schwartz M, Parras G: Saddle nose deformity: Autogenous graft repair. *Facial Plast Surg* 6:121-134, 1989
16. Murakami CS, Cook TA, Guida RA: Nasal reconstruction with articulated irradiated rib cartilage. *Arch Otolaryngol Head Neck Surg* 117:327-330, 1991; discussion 331
17. Toriumi DM, Josen J, Weinberger M, et al: Use of alar batten grafts for correction of nasal valve collapse. *Arch Otolaryngol Head Neck Surg* 123:802-808, 1997
18. Tardy ME Jr, Toriumi D: Alar retraction: Composite graft correction. *Facial Plast Surg* 6:101-107, 1989